



PATIENT

Henri Valentine

SPECIES

Canine

BREED

Chihuahua

SEX

MN

AGE

6 y

WEIGHT

6.5 lb

PRESENTING CLINICAL SIGNS

Murmur. Pre-anesthetic evaluation (dental).

ECHOCARDIOGRAPHIC FINDINGS

2D, M-mode, and Doppler study.

Left atrial size is normal. The mitral valve appears normal, though trace mitral regurgitation is present. Left ventricular dimensions are normal. Left ventricular systolic function is hyperdynamic. The aorta and aortic valve are normal. Right atrial and right ventricular dimensions are normal. The tricuspid valve leaflets are mildly thickened, and a mild jet of tricuspid regurgitation is present. The pulmonary artery and pulmonic valve are normal. No pericardial effusion or cardiac masses are seen.

ECG during echo: Sinus rhythm

LA - 18.2 mm

LA/Ao - 1.37

LVIDd - 18.1 mm

LVIDs - 8.8 mm

FS - 51.4%

RA - 14.2 mm

LVOT - 1.08 m/s

RVOT - 0.91 m/s

INTERPRETED BY

Keith Blass, DVM, MS,
DACVIM (Cardiology)

IMAGING PERFORMED BY

Karen Ebersole, DVM,
DABVP

HOSPITAL NAME

Scanvet

REFERRING VET

Dr. Peyser

INVOICE

DATE

2/17/26

ASSESSMENT/RECOMMENDATIONS

Degenerative tricuspid valve disease

This examination demonstrates mild regurgitation of blood across Henri's tricuspid valve resulting from degenerative valve disease. The hemodynamic effects of the regurgitation also appear to be mild, as Henri does not have secondary dilation of either of his right heart chambers. As such, Henri's current risk for the development of right-sided congestive heart failure appears to be low.

Henri's cardiovascular risk for general anesthesia is low based on this exam, though I still recommend avoiding the use of alpha-2 agonists in the anesthetic protocol and reducing the IV fluid rate by 15% as precautions.

No therapy is recommended at this stage of disease.

A recheck echocardiogram is recommended in 6-9 months.



PATIENT

Henri Valentine

SPECIES

Canine

BREED

Chihuahua

SEX

MN

AGE

6 y

WEIGHT

6.5 lb

INTERPRETED BY

Keith Blass, DVM, MS,
DACVIM (Cardiology)

IMAGING PERFORMED BY

Karen Ebersole, DVM,
DABVP

HOSPITAL NAME

Scanvet

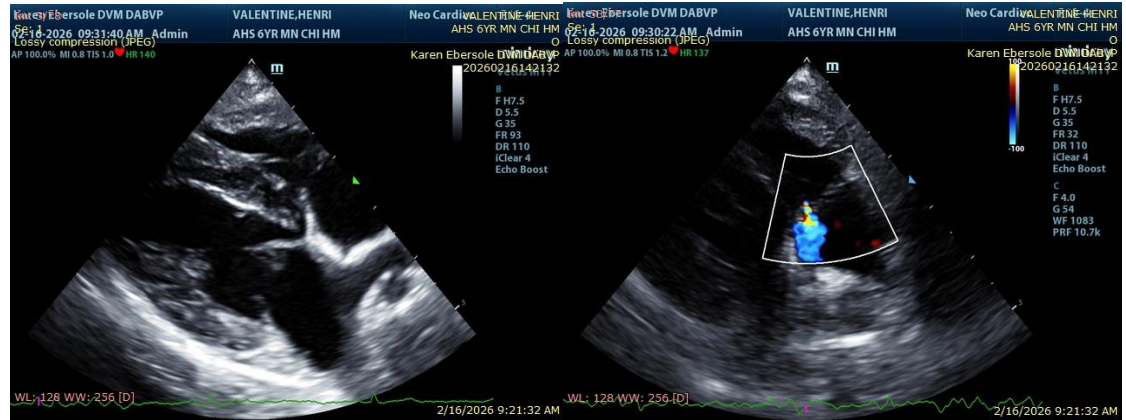
REFERRING VET

Dr. Peyser

INVOICE

DATE

2/17/26



The information and recommendations provided are based on the images presented by the referring veterinarian/sonographer. No evaluation can be communicated regarding pathology that was not visible in the image/video clips provided.

Thank you for this referral. If the clinical or image interpretation does not parallel your findings or if I can be of any further assistance please contact me.

Keith Blass, DVM, MS, DACVIM (Cardiology) info@SonoPath.com